

WOMEN'S HEALTH AND PAEDIATRICS

PAEDIATRIC DEPT

**Facial Nerve Palsy Guideline**

Amendments			
Date	Page(s)	Comments	Approved by
Nov 2008	New Guideline		Paediatric Guideline Group
Feb 2012			Paediatric Guideline Group
Jan 2014			Paediatric Guideline Group
March 2018		Whole document review	Paediatric Guideline Group

**Compiled by:** Dr Clare Hill Consultant Paediatrician

**In Consultation with:**

**Ratified by:** Paediatric Guidelines Group

**Date Ratified:** Nov 2008

**Date Reviewed:** Jan 2021 Dr Erin Dawson

**Next Review Date:** Jan 2025

**Target Audience:** Doctors, nurses and support staff working in Paediatrics

**Impact Assessment Carried**

**Out By:**

**Comment on this**

**Document to:** Dr Clare Hill Consultant Paediatrician

**Guideline for the Management of Acute Peripheral Facial nerve palsy**

**Bells Palsy – in Children**

**Definition**

- Bell palsy is an **acute, idiopathic unilateral lower motor neurone facial nerve palsy** that is not associated with other cranial neuropathies or brainstem dysfunction.
- Common disorder between the ages of 10-16
- Usually develops suddenly. The cause is usually unknown but may develop several weeks after a systemic viral infection
- Most children recover completely.
- Assessment of Bell's palsy is aimed at confirming the diagnosis and excluding the other important causes of facial weakness.

**Causes**

\*Idiopathic – Bell Palsy

\*Infective

- Herpes virus type 1
- Herpes zoster (Ramsay – Hunt syndrome)
- Lyme disease
- Otitis media or cholesteotoma

Trauma – e.g base of skull fracture

Neurological

- Guillian Barre
- Multiple sclerosis
- Mononeuropathy – e.g due to sarcoidosis

Neoplastic

- Posterior fossa tumours
- Parotid gland tumours

Hypertension

(\*These are the most common causes in children)

**History –Red Flags suggestive of other causes of Facial Nerve Paralysis**

History and examination should ensure that the facial nerve is the only cranial nerve involved and there are no other neurological symptoms

There are a few areas of the history which should be explored in particular ask about:

- Onset gradual over >2 weeks - Suggests mass lesion
- Forehead not involved - Suggests central nervous system cause (supranuclear lesion)
- Bilateral involvement - Suggests Polyneuropathy
- Recent travel history – particularly to areas where ticks are known to be present consider Lyme Disease
- Fever - Consider infectious cause such as Otitis Media
  
- Rash - Vesicular rash (Herpes Zoster), Erythema Migrans (Lyme Disease)
- Ear pain – prominent feature of Herpes Zoster infection

**Examination:**

First Ratified Nov 2008	Latest Reviewed March 2018	Version Number: 3	Page 2 of 5
----------------------------	-------------------------------	-------------------	-------------

Need to complete a full neurological examination - cranial and peripheral nerves.

In addition ensure you examine the **ear canal and tympanic membrane, parotid gland, mouth and pharynx.**

### Clinical signs:

It is important to differentiate between an upper and lower motor neurone lesion on clinical examination - in a lower motor neurone lesion the patient will be **unable** to wrinkle their forehead in addition to the other features listed below:

- The upper and lower portions of the face are paretic
- Weakness of the muscles of facial expression and eye closure
- Loss of facial creases and nasolabial fold
- The corner of the mouth droops
- Patients are unable to close the eye on the affected side, decreased tear production – which can cause damage to the conjunctiva and cornea
- In about 50% of cases taste on the anterior 2/3rds of the tongue is lost on the affected side
- Hyperacusis

### Investigation:

- Check Blood pressure ( 2 cases of coarctation presenting with facial nerve palsy and hypertension)
- Serology – in selected cases lyme, herpes and zoster (paired samples 4-6 weeks apart). It may not influence management, but may reveal aetiology.

### Management/Treatment

Main aims are to speed recovery and to prevent corneal complications

Eye care – to protect the cornea from drying and abrasion

- If necessary an eye pad or goggles to protect the eye
- Frequent use of artificial tears during the day (e.g Hypromellose 0.3% eye drops)
- Eye ointment (e.g Lacri-Lube) to lubricate the eye overnight along with a protective eye patch overnight. Another option is to tape the upper and lower lid together when you are asleep.
- Consider referral to eye clinic for examination/advice

### Corticosteroids

- The role in treatment of Bell's palsy in children is unclear, however steroids appear to benefit adults, particularly if given within 72 hours of onset and if complete palsy present.
- **Prednisolone (1mg/kg/day PO daily max 50mg) for 10 days may be considered for Bell's palsy presenting within 72 hours of onset - treat as early as possible, recovery has been shown to be better with early treatment.**

### Antiviral agents

- There is little evidence for the use of antivirals in the absence of any vesicles
- **Always use acyclovir for Ramsay Hunt syndrome** (Consult BNF for Children for dosage)

First Ratified Nov 2008	Latest Reviewed March 2018	Version Number: 3	Page 3 of 5
----------------------------	-------------------------------	-------------------	-------------

- **Currently insufficient evidence to recommend its use routinely** – however it may be considered particularly in patients whose facial palsy is severe

Treat any associated/causative condition

### **Guidance for Parents**

- No need for routine hospital follow up
- Reassurance – most cases resolve spontaneously
- Prognosis - 85% recover spontaneously with no residual facial weakness. 10% have mild facial weakness and 5% will be left with permanent facial weakness.
- Course - Maximal weakness at 3-7 days after onset, most cases improve within 3 weeks even without treatment, additional improvement may require up to 6 months. (No recovery within 3 weeks is associated with a worse prognosis)
- Complications - Corneal Ulceration, permanent eyelid weakness, permanent facial asymmetry

### **References**

1. Holland NJ, Weiner GM: Recent developments in Bell's Palsy. BMJ Sept 2004 4;329 553-7
2. Sullivan FM, Swan IR, Donnan PT, et al; Early treatment with prednisolone or acyclovir in Bell's palsy. N Engl J Med. 2007 Oct 18;357(16):1598-607.
3. Salinas RA, Alvarez G, Ferreira J; Corticosteroids for Bell's palsy (idiopathic facial paralysis). Cochrane Database Syst Rev. 2004 Oct 18;(4):CD001942.

First Ratified Nov 2008	Latest Reviewed March 2018	Version Number: 3	Page 4 of 5
----------------------------	-------------------------------	-------------------	-------------

## **Bells Palsy: Parent/Patient Information**

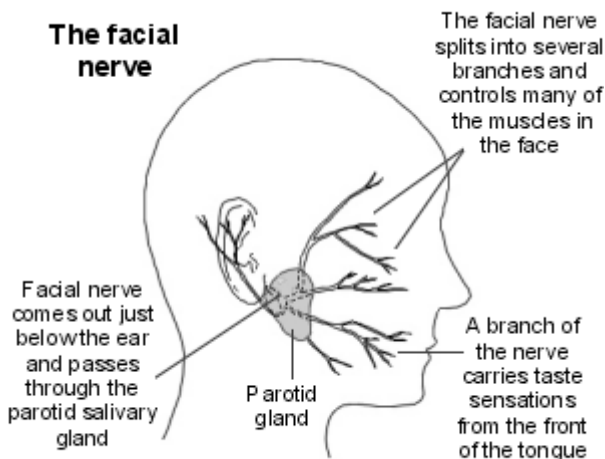
### **What is Bells palsy?**

Bell's palsy is a weakness of the facial muscles. It is due to a problem with the facial nerve. The weakness develops suddenly, usually on one side of the face.

Symptoms of Bells palsy include: Drooping of the mouth and face, difficulty chewing, drooling, inability to close the eye causing a watery or dry eye, sensitive hearing and loss of taste sensation on the side of the tongue that is affected.

### **The facial nerve**

Each facial nerve comes out from the brain, through a small tunnel in the skull just under the ear. The nerve splits into many branches which supply the small muscles of the face used to smile, frown, etc. It also supplies the muscles that you use to close your eyelids. Branches of the facial nerve also take taste sensations from your tongue to your brain.



### **What causes Bell's palsy?**

It is thought that inflammation develops around the facial nerve as it passes through the skull from the brain. The inflammation may squash the nerve as it passes through the skull. The nerve then partly, or fully, stops working until the inflammation goes. If the nerve stops working, the muscles that the nerve supplies also stop working. The cause of this inflammation is not known, but it is probably due to a viral infection.

### **How does Bell's palsy progress?**

In most children the function of the nerve gradually returns to normal. Symptoms usually start to improve within 2-3 weeks, and have usually resolved by two months. In some cases, it can take up to twelve months to fully recover. In a few children, symptoms do not completely go and some facial weakness may remain for good. However, it is often a slight weakness of part of the face and hardly noticeable.

### **What is the treatment for Bell's palsy?**

Without treatment, full recovery is still likely and occurs in about 8 in 10 cases. A course of steroid tablets started within 72 hours of the onset may improve the chance of full recovery even further.

Steroid tablets (prednisolone) are usually prescribed for 10 days, these help to reduce inflammation.

As you cannot fully close your eyelid, the front of the eye may become damaged. The eye can also become dry as the tear gland may not work properly. If necessary the doctor will prescribe eye drops to lubricate the eye during the day and an eye ointment to use at night. It may also be necessary to cover the eye with a patch or tape the upper and lower lids together when you are asleep.