

WOMEN'S HEALTH AND PAEDIATRICS
 PAEDIATRIC DEPT

Periorbital/ Orbital Cellulitis

| Amendments | | | |
|-------------------|---------------|------------------------------------|----------------------------|
| Date | Page(s) | Comments | Approved by |
| April 2015 | New Guideline | | Paediatric Guideline Group |
| March 2018 | | Whole document review – no changes | Paediatric Guideline Group |

Compiled by: Dr Erin Dawson and Dr Eleanor Gridley

In Consultation with:

Ratified by: Paediatric Guidelines Group

Date Ratified: April 2015

Date Reviewed: March 2018

Next Review Date: March 2021

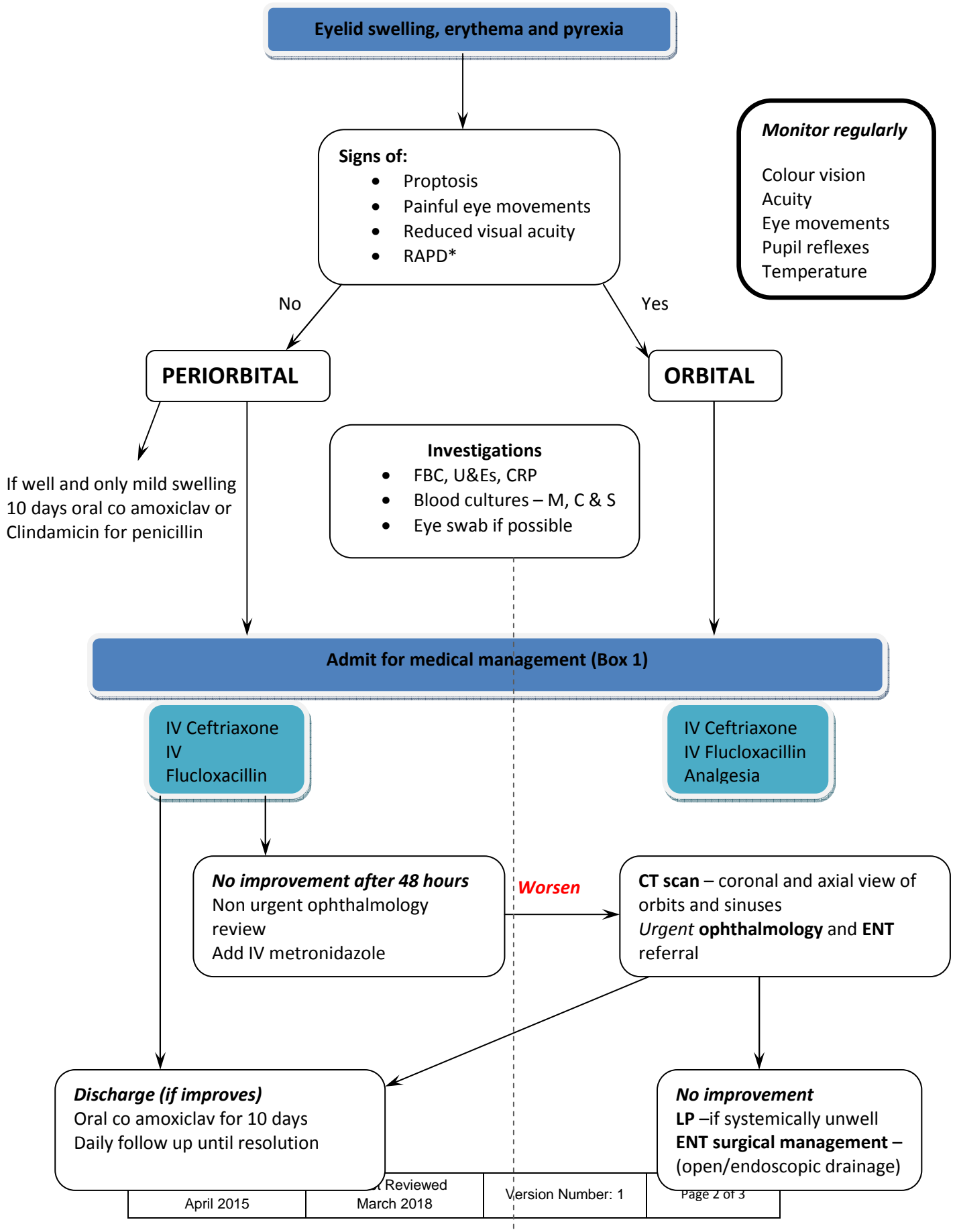
Target Audience: Doctors, nurses and support staff working in Paediatrics

Impact Assessment Carried

Out By:

Comment on this document to: Dr Erin Dawson Consultant Paediatrician

Periorbital/Orbital Cellulitis



Periorbital/ Orbital Cellulitis

Admission Criteria (Box1)

- Proptosis
- Diplopia or ophthalmoplegia
- Reduced visual acuity
- Reduced light reflexes
- When unable to perform a full eye examination
- Systemically unwell
- Central nervous signs or symptoms

Aetiology

Periorbital/Preseptal cellulitis

Infection anterior to orbital septum
Associated with recent trauma

Common organisms:

- Strep pyogenes
- Strep pneumoiae
- Staph aureus

Orbital Cellulitis

MEDICAL EMERGENCY

Infection posterior to orbital septum
Associated with recent sinusitis

Common organisms:

- Streptococcus spp
- Staph aureus
- Haemophilus influenza (rarely)

References

Howe, L, Jones, N; Guidelines for the management of periorbital cellulitis/abscess. Clinical Otolaryngol (2004)

Clinical Management Guidelines: Cellulitis preseptal and Orbital; The College of Optometrists (2011)

Botting et al; Paediatric pre- and post-septal peri-orbital infections are different diseases: A retrospective review of 262 cases. Pediatric Otorhinolaryngology (2008)